

# HISTOPATHOLOGICAL STUDIES ON INTESTINE OF GALLUS DOMESTICUS INFECTED WITH CESTODE PARASITES

S. D. PATIL\* AND HEMLATA S. CHAUDHARI (WANKHEDE)<sup>1</sup>

Department of Zoology, Mahatma Gandhi Vidyamandir's M. S. G. College, Malegaon, Nashik - 422 003

<sup>1</sup>Department of Zoology, Dr. Babasaheb Ambedkar Marathwada University, Aurangabad – 431 004, (M.S.) INDIA

E-mail: sunilpatil991@gmail.com

## KEY WORDS

*Raillietina corvina*  
Histopathology  
*Choanotaenia* sp.  
*Gallus domesticus*  
Crypts of Lieberkhun

Received on :  
02.08.2011

Accepted on :  
27.10.2011

\*Corresponding  
author

## ABSTRACT

The cestode parasites *Raillietina corvina* and *Choanotaenia* sp. found infected to the avian host *Gallus domesticus*. Histopathological studies have been made to assess the extent of damage caused by the parasites. It includes destruction and extrusion of intestinal villi, inflammatory fibrosis due to cysts. *Raillietina corvina* heavily destroyed, rupturing the villi, piercing through submucosa. So the scolex of *Raillietina corvina* is penetrative type (Shinde and Mitra, 1980). The extent of damage is proportional to the penetration of scolex. Cysts found encircled with connective tissue sheath deep in the submucosa. Scolex of *Choanotaenia* sp. is penetrative type as two scoleces found deeply pierced in submucosa of intestine

## INTRODUCTION

In *Pseudanthobothrium*, the bothria are without loculi and cover only the tips of villi like a cap, but the rostellum is very long and penetrates into closely packed villi and the terminal sucker attached to the wall of the villus (Williams, 1966). In Cyclophyllidea, many genera like *Dipylidium canium*, *Cotugnia bhalariaoi*, *Raillietina tetragona*, *Echinococcus granulossus* are studied for histopathology, host-parasite relationships. Some scoleces were penetrative type and others were non- penetrative type (Shinde and Mitra, 1980). In penetrative type attachment is very intimate and crypts of Lieberkhun are invaded while in non- penetrative type it superficially attached to mucosal epithelium of intestinal villi. Important contributions in this direction were made by Joshi and Kamalpur (1971); Mitra and Shinde(1981); Jadhav and Shinde(1981); McDonough and Gleason (1981); Tuli *et al.*, (1992); Reddy *et al.* (2006); Banarjee *et al.* (2006); Patil and Chaudhari (2010). Histopathology revealed disseminated erosion at the site of attachment, lymphocyte migration and hyperplasia of connective tissue in the lamina propria (Ivona, 2006).

In the present study an attempt has been made to visualize the histopathological changes that are caused to the intestine of avian host *Gallus domesticus* due to infestation of cestode parasite *Raillietina corvina* and *Choanotaenia* sp.

## MATERIALS AND METHODS

Intestines of host bird *Gallus domesticus* were examined and

observed to see the degree of infection. The worms which were attached to the intestine were kept intact and small pieces of intestine were fixed in Bouin's fixative and then washed thoroughly. These were then dehydrated through ascending alcohol grades, cleared in xylene and embedded in paraffin wax (M.P. 52°-54°C). The transverse and longitudinal sections were cut on rotary microtome and stained with Haematoxyline-eosin method.

## RESULTS AND DISCUSSION

*Raillietina corvina* n. sp. Fuhrmann (1905) heavily destroyed, rupturing the villi, piercing through submucosa. So the scolex of *Raillietina corvina* is of penetrative type (Shinde and Mitra,1980). The intestine was heavily infected, so most of intestinal villi were ruptured. Attachment of scolex was by rostellar hooks and suckers (Fig. 2). In the lumen of intestine few free gravid segments were found. Few mature segments were invaded by villi. Scolex of *Choanotaenia vithaiae* n.sp. is of penetrative type, as two scoleces found deeply pierced in submucosa of intestine. Scoleces attached by rostellar hooks as well as by spines of suckers (Fig. 4).

*Choanotaenia vithaiae* n. sp. was found in posterior part of intestine. Two cyst of *Choanotaenia vithaiae* near to each other (Fig. 5) and single large cyst of *Raillietina corvina* found deep in submucosa, although touch the muscularis externa (Fig. 3). The cysts are large, rounded and encircled with connective tissue covering. Transverse sections of mature proglottids were found in lumen of intestine.

Various helminth parasites shows pathological consequences




Figure 1: Non-infected intestine of *Gallus domesticus*

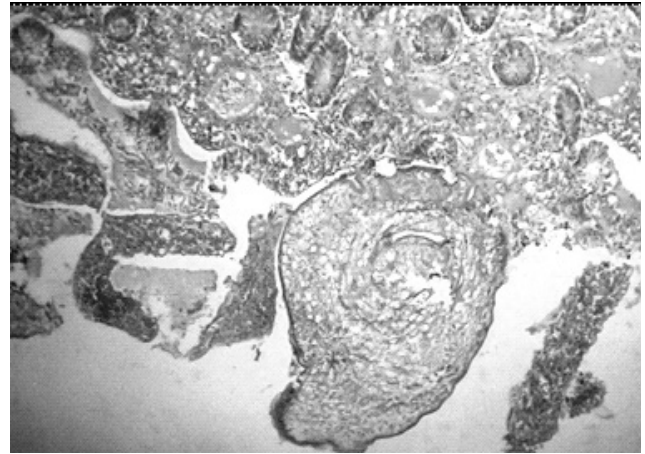


Figure 2: Scolex of *Raillietina corvina* attached to intestinal mucosa

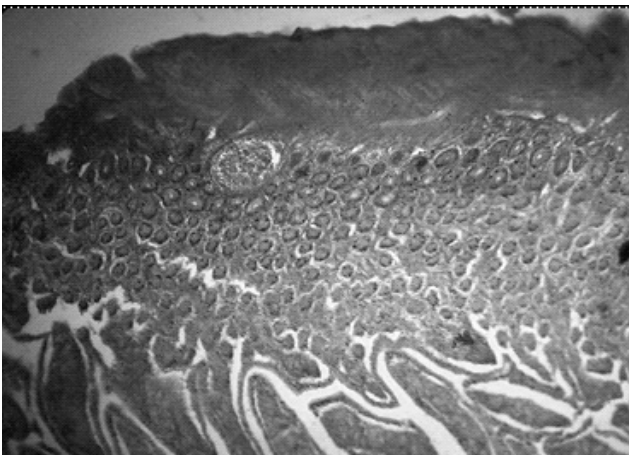


Figure 3: Cyst of *Raillietina corvina* present deep in submucosa

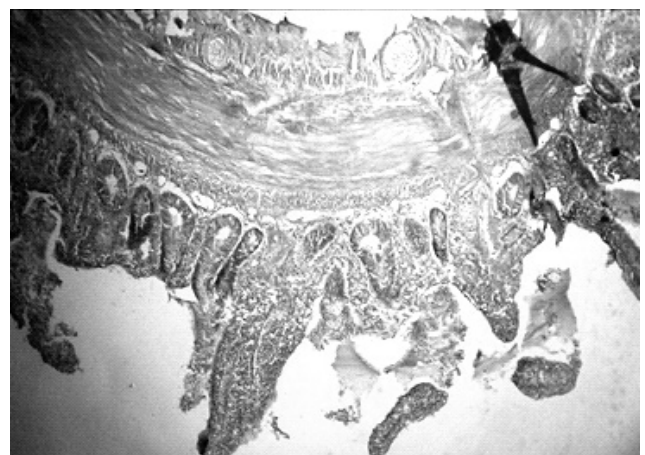


Figure 4: Scolex and mature proglottids of *Choanotaenia* sp. among villi

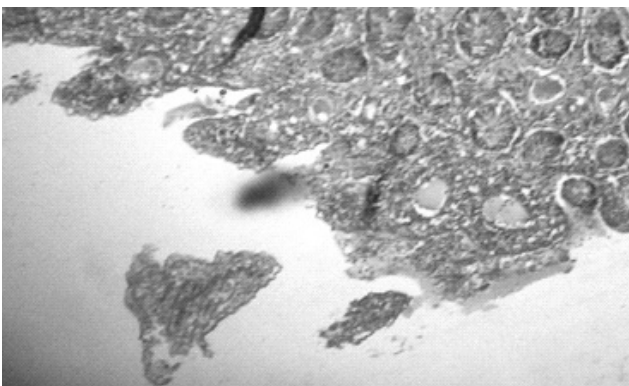


Figure 5: Cysts of *Choanotaenia* sp. present in submucosa

of parasitic effects on birds are well documented. Cestode parasites influences the avian health, causes morbidity and also mortality which pose a major threat to avian population. (Chincholkar and Shinde,1956) However, the extent of damage depends upon depth of penetration of scolex, type and number of cestode parasite and site where they localize in the body of host (Paperna and Zwerner, 1976).

Fig.1 shows intact intestinal villi of non-infected host. The infected intestines were looked diseased with swellings blood clot, all along the alimentary canal and bleeding at certain

places. Histopathology revealed disseminated erosion at the site of attachment, lymphocyte migration and hyperplasia of connective tissue in the submucosa (Ivona, 2006).

## CONCLUSION

The worms *Raillietina corvina* Fuhrmann (1905) are penetrative type and it pierces through crypts of Lieberkhun, mucosa and up to the submucosa layer. It poses a serious threat to the birds. The extent of damage or pathogenic conditions depends on number of invasive parasites and the site where they localize in the host body.

Free gravid segments mostly found in the posterior region of intestine while mature segments are freely suspended from scoleces in the lumen of intestine, only scoleces remain attached, either superficially (non-penetrative type) or deep in submucosa (Penetrative type). The lesions observed on the intestinal wall of the infected birds may be due to the severe infestation or heavy worm burden (Luka and Ndam, 2007).

## ACKNOWLEDGEMENT

We acknowledge the Head, Department of Zoology, Dr. Babasaheb Ambedkar Marathwada University, Aurangabad

(M.S.) for providing necessary laboratory facilities.

## REFERENCES

- Banarjee, G., Reddy, B. L. and Bikshapti. 2006.** Histopathology and Histochemistry of the intestine of *Clarias batrachus* due to trematode *Genarchopis goppo* (Ozaki, 1925). *J. Aqua. Biol.* **21(2)**: 257-262.
- Chincholkar, L. N. and Shinde, G. B. 1956.** Studies on morphology of *Cotugnia celebensis* Yamaguti (Cestoda: Davaineidea) Part IV: Histology. *Acta. Para. Pol. Poland.*
- Fuhrmann, O. 1905.** Die Cestoden der Vogel. *Zool. Jahrb. Syst.* pp. 22-330.
- Ivona, M. L. 2006.** *Hepatoxylon trichuri* (Cestoda; Trypanorhyncha) Plerocercoids in cage-reared northern blue fin tuna *Thunnus thunnus* (Ostiecthyes: Scombridae). *Acta. Adriat.* **47(1)**: 79-83.
- Jadhav, B. V. and Shinde, G. B. 1981.** *Cotylorhipis sureshi* n. sp. (Cestoda: Dilepididae) from *Gallus domesticus* at Aurangabad. *Bioresearch.* **5(1)**: 93-94.
- Joshi, S. C. and Kamalpur, S. K. 1971.** Occurrence of *Cotugnia bhaleraoi* (Madaliar, 1943) in desifowl in M.P. and some observations on its histopathology. *Indian Vet. J.* **48**: 895-898.
- Luka, S. A. and Ndam, I. S. 2007.** Gastrointestinal parasites of chickens *Gallus gallus domesticus* (Linnaeus, 1758) in Samaru, Zaria, Nigeria. *E. World J.* **2(1)**: SWJ: 27-29.
- McDonough, J. M. and Gleason, L. M. 1981.** Histopathology in rainbow derter *Etheostoma caeruleum* resulting from infections with the acantocephalons *Pomporhynchus bulbocolli* and *A.dinu*. *J. Parasitol.* **67**: 403-407.
- Mitra, K. B. and Shinde, G. B. 1981.** Attachment of *Davainea* sp. to the villi of *Gallus domesticus*. *Bioresearch.* **5(1)**: 89-90.
- Paperna, I. and Zwerner, D. E. 1976.** Parasites and diseases of striped Bass *Morone saxatilis* (Walbaum) from the lower Chesapeake bay. *J. Fish Biol.* **9(3)**: 267-287.
- Patil, S. D. and Chaudhari, H. (Wankhede) 2010.** Histopathological studies on intestine of *Columba livia* Gmellin, 1789 infected with cestode parasites. *Environmental Conservation Journal.* **11(1&2)**: 71-73.
- Reddy, L. B., Banarjee, G., Rajender, G., Bikshapthi, V. and Swami, M. 2006.** Histopathological and Histochemical abnormalities induced *Euclinostomum heterostomum* in the liver of fresh water fish *Channa punctatus*. *J. Aqua. Biol.* **21(2)**: 263-267.
- Shinde, G. B. and Mitra, K. B. 1980.** On the host parasite interaction of *Raillietina (Raillietina) tetragona* in *Gallus domesticus* at Aurangabad, India. *Biology.* **II(2)**: 31-34.
- Tuli, J. S., Bali, H. S. and Gupta, P. P. 1992.** Histopathology and Histochemical Studies of intestine in Cestodiasis of poultry. *Ind. J. Comp. Microbiol. Immun. and Inf. Diseases.* **13 (3 and 4)**: 100-104.
- Williams, H. H. 1966.** The ecology, functional morphology and taxonomy of *Echeneibotrium benedeni*, 1849 (Cestoda: Tetrphyllidea), a revision of genus and comments of *Discobothrium benedeni*, 1870, *Pseudobotrium* Alexander, 1963. *Parasit.* **56**: 227-285.

